

Mental State Examination

The mental state examination is collection of observations

1. Appearance and Behavior

The appearance, manners and behavior of the patient may be of importance when there is significant deviation from his/her socioeconomic group.

The style of dress and behavior vary with the geographic region of origin and socioeconomic status of the individual, and the fashion of the day. While appearance and behavior demonstrate membership of a certain group in time and place, they may also be a means of expression of individuality, identity or independence from the group. (Lee Redmond of Utah did not cut her fingernails for 30 years and had the world record for long fingernails. All 10 were over 70 cm. She announced her intention to cut her nails in November 2006, but did not do so. It is reasonable to suppose that for Ms Redmond, longer than usual nails expressed her individuality and identity).

Just as for some people for whom fashion and dancing are revered and practiced art forms, there are others who have no interest in these activities. We do not attributing differences in appearance and behavior (in the absence of additional evidence) to mental disorder.

Appearance

Appearance and personality traits

Appearance may suggest personality traits.

- A high degree of attention to correctness, cleanliness, tidiness and detail suggests obsessional traits. Conservative appearance is also associated with obsessional traits.
- A high degree of attention to fashion may suggest narcissistic traits. Attention to fashion is also a means of belonging to a group, and identifying with ‘celebrities’.
- A high degree of attention to flamboyant or seductive appearance may suggest histrionic traits. Flamboyant appearance may also be a feature of the isolated eccentric or the charismatic leader.

Appearance and mental disorder

Appearance may suggest mental disorder; collaborative information must always be obtained.

The ‘omega sign’ has been described on the forehead of people suffering depression (Grenden *et al.*, 1985). The eyebrows form the bottom of the omega figure and folds pass up and laterally from the glabella (Verraguth’s folds) to be joined superiorly by horizontal wrinkles. This is consistent with increased activity in the Corrugator supercilii muscle, which draws the eyebrows down and medially and was described in Gray’s Anatomy (Davies and Davies, 1962) as ‘the principal muscle in the expression of suffering’.

The ‘long face’ has also been described in depression. The distance from the outer corners of the eyes to the corners of the mouth has been shown to be significantly greater in those with depression than in those without depression, using a method of quantification of facial expression (Katsikitis and Pilowsky, 1991). This is consistent with decreased activity of the Zygomaticus major and Zygomaticus minor muscles, allowing the bottom half of the face to sag or lengthen (generating the idiom, “a face as long as a fiddle”). These muscles are inserted into the corner of the mouth and draw the mouth up and outward, as in laughing. Electromyographic studies support the theory of increased activity in Corrugator supercilii and decreased activity in Zygomaticus minor and Zygomaticus major in depression (Carney *et al.*, 1981) (Figure 5, 6).

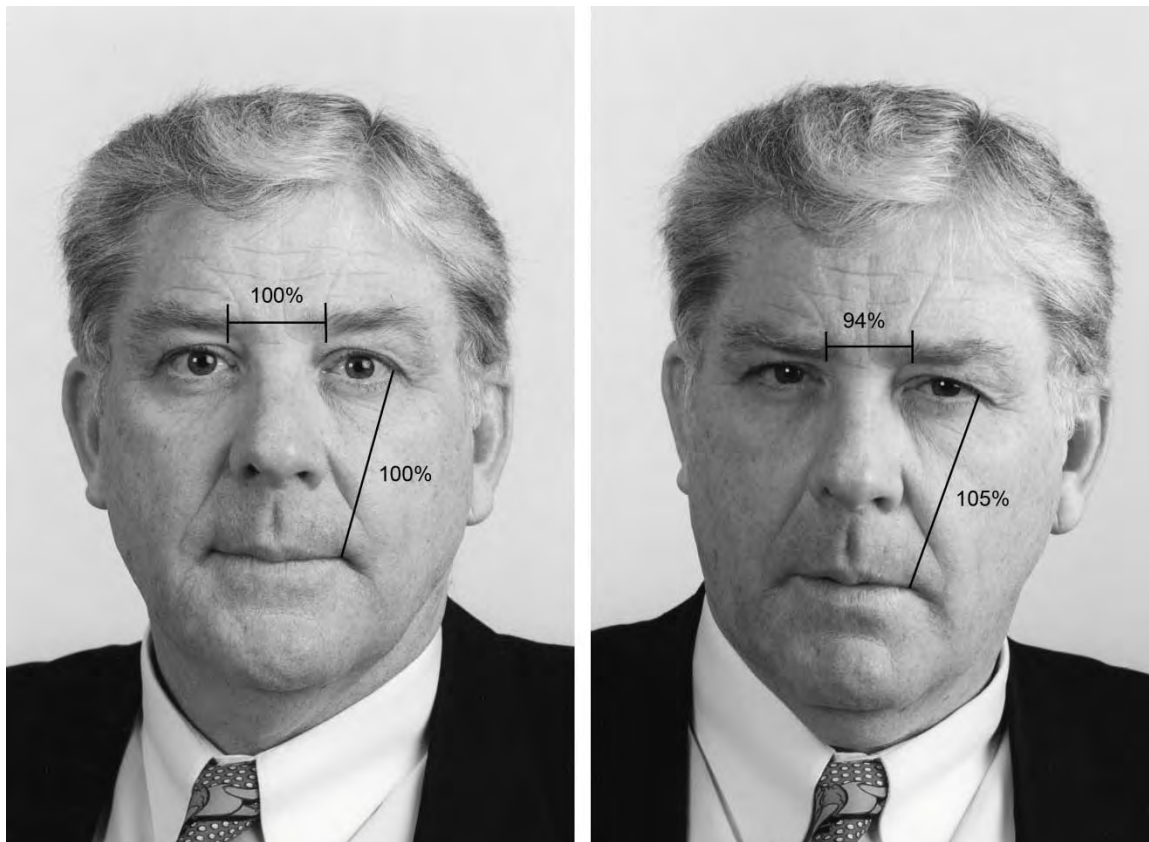


Figure 5. This is the face of an actor. On the right is a portrayal of the facies in depression. The eyebrows are drawn down and together and the omega sign and Verraguth's folds appear on the forehead. The face is 'long' in in so far as, relative to the outer corners of the eyes, the comers of the mouth are lower than periods of remission. The mouth is also less wide. The portrayal on the left is for comparison, with a neutral, not smiling expression.

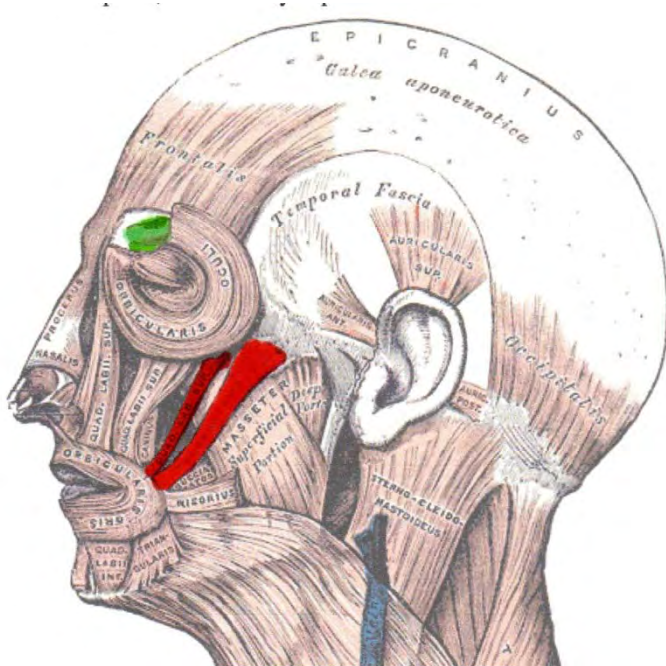


Figure 6. The muscles of the left side of the face. The Corrugator supercilii muscle is shown in green - a short muscle above the medial part of the eye. The Frontalis and the Orbicularis oculi muscles have been cut away for demonstration purposes. The Zygomaticus major (wider) and minor (narrower) muscles are shown in solid red, running from a bony arch between the eye and the ear, to the corner of the mouth.

Bizarre appearance, such as the wearing of special headgear to protect against radiation, suggests psychosis, but is quite rare. Less dramatic changes in appearance associated with psychosis are more common. These include uncharacteristic shaving of the head (especially when performed by the individual himself and scrapes and scabs adorn the head, or the prominent wearing of religious insignia where none were worn before. Mood elevation may result in 'dramatic' appearance and behavior (Figure 7).



Figure 7. A middle aged woman was admitted to a psychiatric ward in a manic state. While on the ward she used acrylic paint to put the words “kindness, joy, peace, patience” on the front, and “I love (indicated by symbol of a heart) life”, “Love” and a patriotic slogan on the back, on a pair of expensive new jeans. She then wore these with confidence.

Self-neglect of recent onset as when a patient presents in relatively new and expensive clothes but with food stains on the front or smelling of urine and body odor may suggest an organic disorder such as rapidly progressing dementia, or very rarely, severe depression with psychomotor retardation.

Self-neglect of long standing, such as when a person who has had extensive dental attention evidenced by gold fillings presents with many cavities and poor oral hygiene, suggests a chronic disorder such as schizophrenia.

Colorful clothes as when a patient presents wearing bright prime colors may suggests mania. There may also be excessive use of jewelry, and necklaces and earrings may be wrapped around wrists or pinned to the front of the clothes.

Somber clothes (dark colors) may be a feature of depression. This is never particularly striking. It may become so in retrospect, however, when the recovering patient begins to wear colors.

Behaviour

Restlessness (inability to remain at rest/still, also termed over-activity) is marked by frequent, quick, large amplitude (often) movements of the hands, the demonstration of points with actions, standing to walk around, and unexpected leaving of the room (occasional). The voice may be loud and the speech rapid. The face is often smiling, and the behavior playful. (Figure 8.)

Restlessness/over-activity may also feature in attention deficit disorder, delirium, thyrotoxicosis, stimulant abuse and akathisia (a side effect of antipsychotics, particularly the older types).

Agitation refers to restlessness and a measure of distress. Agitated depression is a serious form of depression, often considered to be depression combined with anxiety – the anxiety apparently underpinning the movement. Here the restlessness/over-activity takes the form of writhing while seated, highly distressed/tense facial expression, and classically, wringing of the hands. These patients are unlikely to be threatening/intimidating toward others. They are, however, at risk of aggressive action directed toward the self (suicide). In agitated depression and paranoid states, rather than loud voice, there may be frequent, distressed whispering to the self.

Highly agitated individuals with high levels of distress may become threatening/intimidating (rare). When there is any risk, staff must have assistance close at hand. Ideally, interview offices have two exits, on opposite walls, so that both patient and clinician are able to vacate unhindered.

Threatening/intimidating behavior may take the form of raised voice or shouting, standing very close to the interviewer, unblinking staring, and raised hands or fists. This may be found with intoxicated individuals, aggressive individuals with no psychiatric disorder, aggressive antisocial personality disordered individuals and psychotic individuals with persecutory delusions. Staff must not tolerate such behavior.

As mentioned, mania usually manifests restlessness/over-activity and joviality (initially). However, the joviality may be replaced by irritability/intimidating behavior as an episode progresses, or if the patient is obstructed, as when prevented from leaving hospital. Occasionally, from the start, there is no evidence of joviality and the dominant state is irritability.



Figure 8. This construction was made by a reserved young geologist during an acute manic episode. She had been admitted to hospital but slipped away and went into a bank -where she was neither a customer nor known. The source of the toy bears remains a mystery to all, including the patient. She constructed this article at a customer desk. She asked the tellers for items as she required them. She first asked for scissors and cut cardboard promotional material to form the components of the sign post. She asked for colored paper from which she cut the letters. She then asked for the use of a stapler and glue and had other discussions. The 'HI!' is composed of three layers of ever smaller letters, first pink, then white and finally very small black letters. In other circumstances the construction may have been more colorful, but banks stock limited creational materials.

Once completed, this construction was carried by the patient as a greeting placard along the streets back to the hospital (where she made a gift of it to her treating doctor). For this usually demure young person, carrying this construction in public constituted bizarre appearance and behavior.

It was surprising that this patient, who was so disorganized as to have no memory of the acquisition of the toy bears, had organizational and concentrational abilities sufficient to perform this quite delicate work. But in mania (and many other mental disorders), psychopathology is notoriously variable and patchy.

Decreased activity often takes the form of sitting still with reduced hand gestures and facial movement. Movements may be slow and the talk, slow and monotonous (see later). Thought may also be slow. If there is generalized slowing and, on questioning, the patient is aware of slowed thought (“And, is your thinking fast, normal or slow?”) the term ‘psychomotor retardation’ may be applied. While the observer can conclude there is ‘motor retardation’, by convention, unless the patient admits to slowed thoughts, ‘psychomotor retardation’ is not applied - it would be arrogant to decide the thinking is slow in the face of the patient’s denial. The interviewer may have a strong sense that thought is slow, and the patient may lack insight, but convention holds.

The above paragraph best describes acute depression. Chronic schizophrenia (with pronounced negative symptoms), mental retardation, hypothyroidism and Parkinsonism (idiopathic and drug induced) must all be considered.

Repetitive movements include ‘tics’ and ‘stereotypy’. Tics are sudden non-rhythmic movements (such as shoulder shrugging) or vocal productions (including sniffing). They are involuntary but can be voluntarily suppressed. Transient tics may appear in healthy individuals at times of stress. Tics which may fluctuate in severity occur in Tourette’s syndrome, obsessive compulsive disorder and attention deficit disorder. Huntington’s disease and Wilson’s disease also have movement pathology and need to be considered.

Stereotypy is intentional, repetitive, non-functional behavior such as body-rocking or head-banging—stereotypic movement disorder is a DSM-IV diagnosis and occurs with intellectual disability. Stereotypy was once common in schizophrenia but is now uncommon (either the impact of modern treatment or a change in the disease presentation).

‘**Echopraxia**’ is the term applied when the patient unconsciously copies the interviewer’s movements. This is not an act of ridicule. In severe cases it is clearly present, but in less severe cases (which are much more common) it is subtle and easily missed. For example, only some movements may be replicated, the patient crossing the legs or touching the face shortly after the interviewer has done so. Echopraxia is most commonly encountered in schizophrenia, but may be associated with drug intoxication, and drug-induced psychosis. It also occurs to some extent in interactions between normal people, particularly when one individual is charismatic. For example, when a dominant individual extends his/her hand, the other extends his/hers ‘without thinking’. Newly described “mirror neurons” may play a role (Pridmore et al, 2008).

‘Catatonic symptoms’ occur when the pathological mental state is expressed in motor anomalies. They may be categorized as the following.

- ‘Catatonic Stupor’ in which movement and speech ceases and the patient is unresponsive to the spoken word or even to painful stimuli. There is usually also the failure to take food or fluid. Accordingly, the life of the patient may be in danger and active treatment is essential.
- ‘Catatonic Posturing’ in which the patient assumes a posture which is then maintained. This might be a strange posture such as standing on one leg with the arms out sideways in the middle of the front path, but it is usually more subtle and may simply impress as an awkward or uncomfortable way to sit or stand.
- ‘Catatonic Rigidity’ in which a posture is maintained against the interviewer’s attempts to move the limbs or the whole patient.
- ‘Waxy Flexibility’ in which the interviewer can change the position of the patient’s limbs, and in the process the limbs feel to the interviewer as if they are made of wax. (The new posture is usually then maintained for at least a few seconds and sometimes minutes.)
- ‘Negative or Contrary Catatonia’ in which the patient does the opposite of what is expected. The most commonly described is when the patient extends his/her hand to the clinician, the clinician responds by extending his/her hand, and as this action is performed, the patient withdraws his/hers.
- ‘Other Catatonic Symptoms’ include catatonic excitement in which there is extreme activity, including potential violence, and automatic obedience.

Catatonic symptoms of marked form are now seldom seen, and the above list is based on observations from the 18th century (Kahlbaum, 1874). However, elements of the above continue to be observed. The author’s recent clinical experience includes a big man with a forensic history (assault and robbery) and schizophrenia, who would not shake hands. He was observed standing in a passage-way, in front of a food trolley. He would/could not move and the trolley could not pass. This was initially interpreted as an aggressive act, but it became clear this was a catatonic feature akin to classical ‘posturing’. Fortunately, he could be led out of the way. We then concluded that his failure to shake hands was probably not a conscious rejection of others, but a version of Negative or Contrary Catatonia. A first hand account of standing motionless is presented in Figure 9.

“Someone knocked loudly on their window, signaling me to go in their place. They seemed very angry so I didn’t go in. I stopped still at the

corner of Britannia St. and Melbourne Road. This was because I felt Satan was leading me into a trap if I kept on walking. I was as still as a statue. God's peace kept my mind. It started to drizzle lightly, so light that I couldn't feel the rain on my head. After a while a lady came out with her family. They were staring at me strangely. She said "What are you doing here?" I said, "God sent me."

After they went inside, I began to walk down Britannia St. Because I had been standing for about half an hour I found it extremely hard and painful to lift my feet off the ground. Finally, I got into the next street where two policemen met me. They said that six different people phoned up complaining about me. We were talking a while not getting anywhere when I heard a voice say "Go". I later realised that the voice was trying and successful in getting me into trouble. I ran, faster than I had ever ran. After running 100 yards, I stopped. The policemen running after me was 50 yards behind and the police car was just pulling up beside me. They put me in the van. I was cold. Just then Mr. Brown my church Minister came along. He assured the policemen that I was due for a breakdown and that I was a fast runner. Even though I hadn't run fast in years...."

Figure 9. This was written by a young man who suffered schizophrenia and eventually died by suicide. When he wrote that he was as 'still as a statue' for half an hour, in drizzle, he was probably describing a period of catatonia. There is some delusional material in the first paragraph. In the second paragraph he describes a command hallucination to which he responded. The third paragraph has a light-hearted flavor - this may have been intentional; more probably, it is the result of disorganized thinking and affect of the type which may occur in disorganized (hebephrenic) schizophrenia.

'Self-cutting' or 'slashing up' on the arms causes alarm in the observer. It is usually interpreted as an expression of suicidal intention/desire. However, there may be no such desire. A detailed discussion of the difference between failed suicide (where there was strong suicidal desire and action taken to that end, but for one or more of many reasons, there was failure to achieve the desired outcome) and suicidal-like behavior without the intention to die, is beyond the scope of this book. However, experts can usually make the distinction, although in some cases, even the individuals themselves are unsure whether or not they had desired to die.

It is known that many people who complete suicide have a past history self-cutting, over-doses and other forms of self-injury. Thus, self injury is a risk factor for suicide, and people presenting with self injury should be thoroughly assessed and offered follow-up.

There are many other risk factors for suicide, including, male gender, older age, single/divorced, history of depression, heavy alcohol use, unemployment, rural residence etc, but these have not been of any help in reducing suicide rates (Large et al, 2011; Sher, 2011, Pridmore, 2011a).

Here, we are dealing with behavior, and we cannot make conclusions about suicidal intention and possible psychopathology from the site and depth of the cutting. However, if the behavior included preparations to avoid detection, such as taking a hotel room under an assumed name before performing the action, great care is mandatory.

Cuts on the dorsum (outside) of the wrist and forearm have little potential to cause death. However, the lay person may not be aware of this low lethality, thus these actions may still represent a strong intention to die. Cuts on the volar (inner) aspect of the wrist, which sever arteries, nerves or tendons, call for surgical intervention and suggest a strong suicidal desire, and perhaps, but not always, indicate mental disorder such as major depressive or a psychotic disorder (Pridmore, 2009; Pridmore, 2011b).

Self-cutting of the upper limb, amid old scars from previous episodes may represent a maladaptive tension releasing or communication technique, and possibly, features of personality disorder. (Figure 10.) Self-cutting is a common presentation in western Departments of Emergency Medicine, but it is unknown in some regions of the world (Pridmore & Yaacob, 2008).

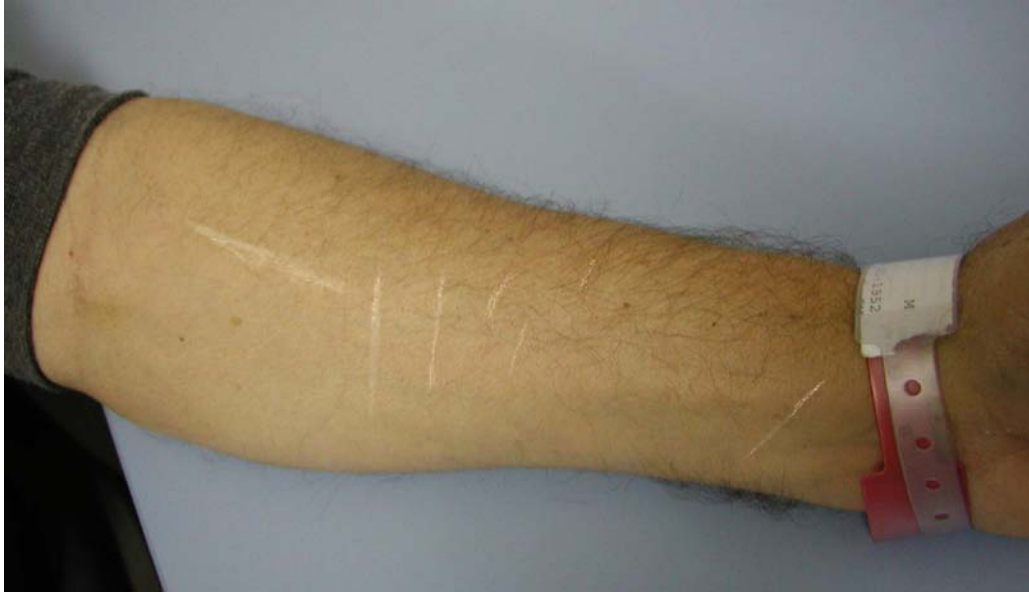

Figure 10. The arm of a man with a history of self-cutting. No diagnostic diagnosis could be made, however, he had borderline, histrionic and narcissistic traits.

‘Self-mutilation’ usually does not carry immediate risk to life and appears to be a different phenomenon. It may involve the removal of body parts such as an eye (Kimber and Pridmore, 2009), finger, penis or external ear, and cuts to the face, body or limbs. Cuts to the body may be to the breasts or genitalia. To be classed as self-mutilation, cuts to the arms and legs must be disfiguring.

Self-mutilation suggests psychotic disorder. In such circumstances the act may be conducted in response to command hallucinations (Figure 11), delusion, or as inexplicable, bizarre behavior (perhaps underpinned by labile affect).

Dr William Minor, a former Union Army surgeon, amputated his penis at age 68 years (1902), apparently as a consequence of delusional thinking (Winchester, 1998). Dr Minor led a remarkable life. He became psychotic and was discharged from the army in his mid thirties and went to England. He murdered a man at the age of 38 years but was found not guilty by reason of insanity, and placed in Broadmore asylum. He was allowed considerable freedom and became one of the largest contributors to the Oxford English Dictionary. He was allowed to leave England and died in Connecticut at 86 years of age.

think are right. They tell
me to stand on your head
and cut the vagina area with
glass and use ^(a towel and smell it for five or six hours) ~~objects~~ ^{on that}
^{drinking cup}
and to go round and round and up down on a
^{machine in a torture chamber.}
area. There's some kind of

Figure 11. This abstract is from an unsigned letter from a woman to a general hospital. Her first lines subsequently had additional smaller words squeezed in between them. Here she writes that "The voices" (hallucinations) tell her to "...cut the vagina area with glass and use objects on that area" Later added smaller word state "...and to go up and down and up and down on a torture machine..." It is not known if she complied with these instruction. Command hallucinations to self-mutilate are not uncommon. Compliance is less common, but does occur. This letter is presented later in more detail later, and another case in which the patient is known to have complied is presented under hallucinations.

Self-mutilation is not exclusive to psychosis. As with non-suicidal self-cutting, self-mutilation may represent a maladaptive tension releasing or communication technique associated with personality disorder (Figure 12). Also in the clinical experience of the author was a middle aged female who removed fingers at different times of stress, yet no diagnosis other than personality disorder could be discovered.

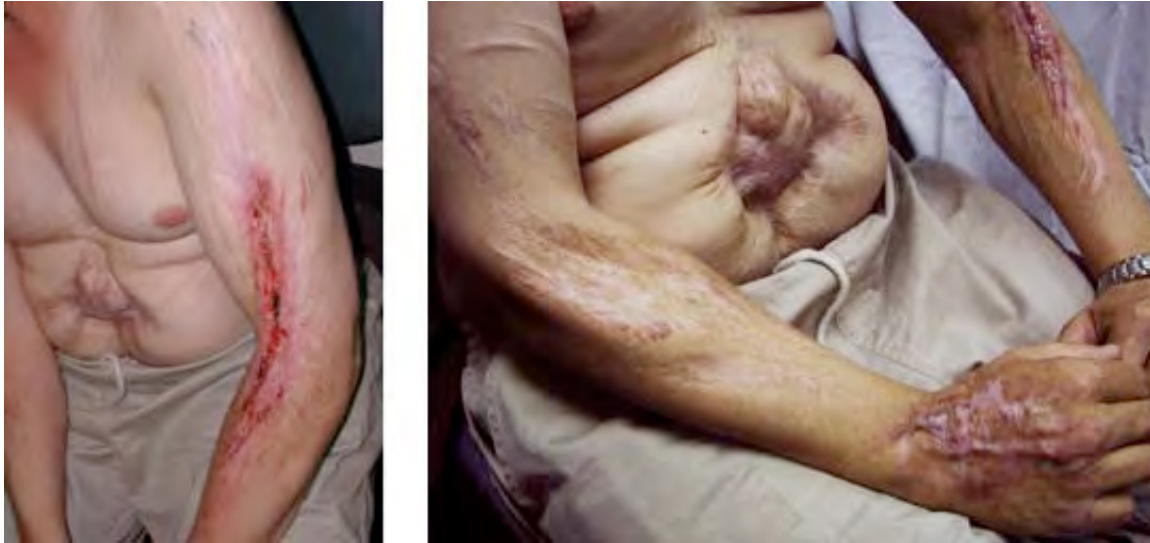

Figure 12. The hands arms and abdomen of a self-mutilating man with a long history of borderline personality. He kept a 30 cm lesion on his left arm permanently open. The edges and the base of the lesion were scarred and indurated. He burnt the dorsum of his right hand and there was muscle tissue loss of his right forearm from repeated injury. There were scars on his upper chest which are not well illustrated in these photographs. In the past he has swallowed razor blades which had perforated his bowel, leading to abdominal surgery. He had repeatedly removed the stitches and recut his abdominal scar, leading to a large incisional hernia. (The bulging in the middle of his abdomen is abdominal organs pushing against scar and skin, the muscle wall of his abdomen having been self-damaged.)

In recent times, self-mutilation has been fashionable among non-psychotic individuals in Australian prisons. One notorious Australian prisoner (murder) earned the nickname 'Chopper' by cutting off his external ears. Such mutilation creates a frightening appearance, but the motivation probably varies with the individual and may include initiation/belonging to a group and self induce punishment, among others. Some decades ago the shaving of the head and tattooing on the face and neck might have been considered low level self-mutilation, but they are now fashionable.

Suicidal behavior other than cutting is not uncommon. This usually precedes presentation, but on occasions, occurs in hospital while the patient is waiting for, or after assessment. It may take the form of self-hanging. In such instances, as there is rarely a strong rope at hand, the attempt may be made with a flimsy article such as a tape measure, with little prospect of causing death. Such behavior may

suggest personality disorder, factitious disorder or malingering. On the other hand, it may symbolize a strong desire for death, and must be fully evaluated.

Bizarre or inexplicable behavior other than self-injury is not common. Examples from the author's experience include the directing of street traffic and painting traffic line on the road without authority, walking naked in the street with clear consciousness, and the unpremeditated fatal stabbing of a child. In each of these cases the patient was psychotic, but other mental disorders and malingering must be excluded.

Hoarding is the acquisition of or inability to discard items which appear (to others) to have no value (Frost & Gross, 1993). There may be a fine line between 'collecting' and 'hoarding'. In hoarding there is often chaos and the hoarded items may limit individuals in living their lives. From time to time we see TV shows about people who have cluttered their houses with valueless items to such an extent that they cannot enter rooms, and the neighbors complain when the yards become so cluttered with "rubbish" that rats take up residence and cause a public health hazard. This may be seen as a matter of civil liberty and choice. In mental disorders, hoarding is often seen in obsessive compulsive disorder, eating disorders, dementia and low intelligence and schizophrenia.(Figure 13)



Figure 13. A man of no fixed abode apparently suffering from schizophrenia was admitted to hospital. His only belongings were in a bag he carried in his hand. In the picture on the left are items which appear to have some value. Among them were 10 watches, all old and broken, two dials (the sort which registered pressure or temperature on old machines) a brass bell, a small stack of notebooks (all empty), a couple of foreign coins, some single earrings and about 20 keys (to unknown locks). In addition, the bag contained (shown on the right) a large quantity of pamphlets, notes, shoelaces and matchboxes, which appeared to have no value whatsoever. The only book was entitled "The Strong Arm of the Law". It

is not possible to be clear regarding the thinking behind this 'collection of material', but such behavior is not uncommon in schizophrenia.

Side-effects of medication

The side effects of medication are many. We deal here only with those which may influence appearance and behavior. Naturally, this applies to patients who have been diagnosed and treated in the past, these features being observed at subsequent presentations.

Weight gain is a feature of all most all psychiatric drugs but most particularly with the newer antipsychotics (e.g., clozapine and olanzapine), and some antidepressants (e.g., mianserin). The mechanisms are complex, but may include reduction of the metabolic rate, histamine blockade (which increases appetite) and cholinergic blockade (anticholinergic effects, which dry the mouth and thus increase fluid intake). Lithium also reduces the metabolic rate, can induce hypothyroidism and increases the fluid intake (blocking antidiuretic hormone).

Drowsiness is also a possible side effect of most psychiatric medications, via a range of actions, including histamine blockade.

Gynecomastia in males and **galactorrhea** and **amenorrhea** in females may result from antipsychotic use (D2 blockade increasing prolactin levels).

Neuroleptic malignant syndrome (NMS; rare) includes muscle rigidity, hyperthermia, autonomic instability and fluctuating consciousness. It is probably due to disruption of dopaminergic function, but the mechanism is not understood. Untreated, the mortality rate is 20%. Renal failure secondary to rhabdomyolysis is a major complication and the cause of mortality. Immediate medical attention is mandatory.

Serotonin syndrome is characterized by sweating, diarrhea, abdominal pain, tachycardia, elevated blood pressure, myoclonus, hyper-reflexia, pyrexia and agitation. Extreme cases may prove fatal. This syndrome is the result of excessive release of serotonin and more likely when different classes of drugs which facilitate serotonin release are used concomitantly.

Extrapyramidal system (EPS) signs are common and more extreme with the typical antipsychotics, but also occur with the atypical drugs. These are due to

blockade of the dopamine receptors of the extrapyramidal system, leaving cholinergic pathways relative unmatched.

- **Acute EPS side-effects** can appear on the first day (or later) of treatment and can take various forms of involuntary movements, particularly of the jaw, tongue, neck and eyes. **Oculogyric crisis** is a dramatic form in which the neck arches back and the eyes roll upward. **Laryngospasm** is a potentially dangerous form is— an early warning sign may be the patient's voice becoming higher pitched. Balance in the EPS can be immediately restored with oral or intramuscular administration of an anticholinergic (e.g., benztropine 2mg).
- **Medium-term EPS side-effects** are of two form. **Akathisia** usually occurs within the first few day of treatment and involves either a mental and/or motor restlessness. The mental restlessness is distressing. The motor restlessness usually affects the lower limbs, with shifting from one foot to the other while standing, and constant crossing and uncrossing of the legs while sitting. This is a difficult condition to manage and expert advice should be sought. **Parkinsonism** usually occurs some days or weeks after the commencement of treatment. There is a mask-like face, rigidity of limbs, bradykinesia (slow movements), and loss of upper limb-swing while walking. Tremor and festinating gait are less common. Management may involve reduction in dose of the antipsychotic (if possible) and the addition of regular anticholinergic medication.
- **Late EPS side-effects** usually occur after months or years of D2 blockade. The mechanism is not clear, but probably involves hyperexcitability of the D2 receptor (a consequence of long periods of blockade). **Tardive dyskinesia (TD)** is the main form and involves continuous choreoathetoid (writhing) movements of the mouth and tongue, frequently with lip-smacking, and may also involve the head, neck and trunk. In young people TD usually takes the form of finger movements and swaying of the trunk. Late EPS side-effects are resistant to treatment, thus, an alert preventive approach is best policy.