

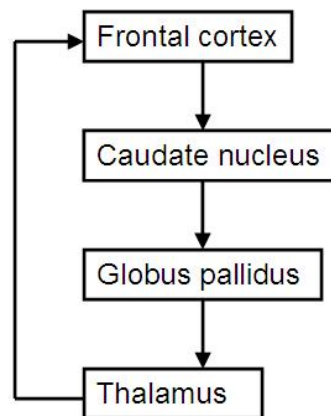
CHAPTER 27

FRONTAL LOBES – BEDSIDE TESTING

Introduction

The frontal lobes, phylogenetically the youngest part, form over half the brain volume. Until recent decades the prefrontal areas were referred to as the “silent areas”, because injury to these regions was not accompanied by sensorimotor signs, and the function of these areas was not clear. The connections of the frontal lobes have now been described (Goldman-Rakic, 1987) and their functions have received much attention (Alvarez & Emory, 2006).

The frontal lobe cortex forms a part of the frontal-subcortical circuits (these have been described in detail in Chapter 2). There are 5 parallel, separate circuits (Alexander et al, 1986). In brief, each circuit has a “direct” and an “indirect” route. The direct route has 4 components and is schematically represented:



The indirect routes are a little more complicated, with a projection from the globus pallidus to the subthalamic nucleus, and another returning from the subthalamic nucleus to the globus pallidus.

These 5 separate circuits form essentially closed loops, however, they receive input from other brain regions. Thus, lesions at various sites, both within the closed loops and outside, may have similar clinical effects. For example, in Alzheimer’s disease the site of most pathology is the cortex, but Huntington’s disease and Parkinson’s present related symptoms of dementia due to subcortical pathology.

The 5 frontal-subcortical circuits

1. a motor circuit originating in the motor cortex and pre-motor cortex
2. an oculomotor unit originating in the frontal eye fields
3. the dorsolateral prefrontal circuit, which underpins executive functions
4. the anterior cingulate circuit which underpins motivation
5. the orbitofrontal circuit which underpins impulse control and social behavior.

The motor circuit and the oculomotor unit are of importance, but of greater interest to neurology than psychiatry. The dorsolateral prefrontal, anterior cingulate and orbitofrontal circuits are of great interest to psychiatry.

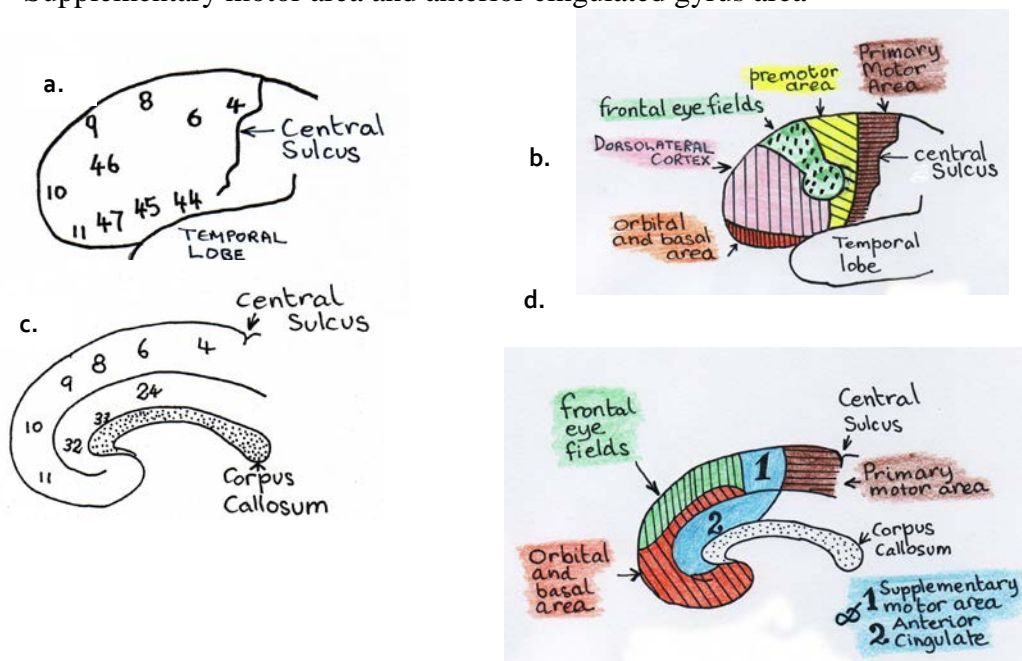
These parts of the frontal lobes allow the organism to learn from experience, and organize current information and choose a course of action, to summon drive to execute the action, and remain attentive and resist distraction.

In the following paragraphs, the “functional regions of the frontal lobes” are discussed. Beside tests are suggested. The intention is to dispel the notion that the frontal lobes are the “silent areas” of the brain, and illustrate that they can be examined, at least to some extent, by an interested doctor.

While there are 5 frontal-subcortical circuits, there are 6 functional regions listed below. This is because the motor and premotor frontal regions both contribute to the motor frontal-subcortical circuit.

Functional regions of the frontal lobes

- I. Primary motor area
- II. Premotor area
- III. Frontal eye fields
- IV. Dorsolateral prefrontal cortex
- V. Orbital and basal areas
- VI. Supplementary motor area and anterior cingulate gyrus area



Illustrations. a: Brodmann areas of the left frontal lobe (lateral view); b: functional regions of the left frontal lobe (lateral view); c: Brodmann areas of the right frontal lobe (medial view); d: functional regions of the right frontal lobe (medial view).

Primary motor cortex

The primary motor cortex or precentral gyrus (bounded posteriorly by the central sulcus) is Brodmann area 4. Although designated a “motor” cortex, this area is also involved with somatosensory perception. Lesions in this area of cortex or the subcortical elements of the associated circuit result in weakness and incoordination.

Bedside tests:

1. Motor strength of hand grip. The patient is asked to grip the examiners fingers. Strength should be roughly equal, with greater strength on the dominant side. It should be difficult for the examiner to free her/his fingers.
2. Motor speed as in finger tapping has also been listed as a useful test (Malloy & Richardson, 1994) but such tests do not discriminate from the premotor cortex.

Diagnostically, poor performances suggest local lesions such as vascular or neoplastic pathology, or a generalized lesion such as a degenerative disease. (Peripheral nerve lesion must, of course, be excluded.)

Premotor cortex

The premotor cortex, a transverse strip, is Brodmann area 6. It is involved in sensorimotor integration. Lesions in this area or the subcortical elements of the circuit cause inability to make use of sensory feedback in the performance of smooth movements and apraxia. Apraxia may also be a result of lesions of other areas (parietal lobe).

Bedside tests:

1. Sensorimotor abilities are tested by asking the patient touch each finger to the thumb in succession as rapidly as possible. Watch for speed and dexterity.
2. Apraxia can be tested by asking the patient to "blow a kiss" and to demonstrate the use of a shovel.

Poor performance carries the diagnostic implications as for the motor cortex above.

Frontal eye fields

The frontal eye fields are largely Brodmann area 8, with some area 9 and 6. Eye movement involves many structures, and a lesion in one may be compensated for by activity in another.

For present purposes, voluntary eye movements are of two types. Pursuit movement occurs when the eyes to follow moving objects. Saccadic eye movements are used to follow imaginary points.

Bedside test:

1. Ask the patient to follow the movement of a finger from left to right and up and down.
2. Ask the patient to look from left to right, up and down (with no finger to follow).

Note inability to move or jerky movement.

Dorsolateral prefrontal cortex (DLPC)

The Brodmann areas for the DLPC are a matter of some disagreement. All agree that area 9 is a large part of the DLPC. Other areas named are 10 and 46. A compromise position is that the DLPC is composed of Brodmann area 9 and the lateral aspect of 10 and most of area 46.

The DLPC and the subcortical elements of the associated circuit are responsible for executive functions. The executive functions include the integration of sensory information, the generation of a range of response alternatives to environmental challenges, the selection of the most appropriate response, maintenance of task set, sequential ordering of data, self-evaluation of performance and the selection of a replacement responses if the first applied response fails.

(The above paragraph is generally accepted. However, as research continues the complexity of the CNS increases. A recent review indicates that executive functions may not solely reside in the frontal lobe (Alvarez & Emory, 2006).)

The executive functions largely determine the ability of the individual to cope with the continuous, but ever changing challenges of the environment. Thus, the patient's ability to make an appointment and to arrive on time is valuable information. So too, is the ability of the patient to give a comprehensive account of her/himself and the reasons for the consultation.

It is believed by some authors that formal thought disorder arises from a lack of executive planning and editing (McGrath, 1991). In thought disorder there are frequent examples of failure to maintain set (distractibility), sequentially order information, and to ensure that the listener is comprehending. [However, formal thought disorder is also known to involve the left superior temporal sulcus and the left temporal pole (Horn et al, 2010).]

Bedside tests:

1. Is the patient able to make an appointment and arrive on time?
2. Is the patient able to give a coherent account of current problems and the reason for the interview? Is there evidence of thought disorder?
3. Digit span, days of the week or months of the year backwards. Here the patient has to retain the task and simultaneously manipulate information.
4. Controlled oral word association test (COWAT): the patient is asked to produce as many words as possible, in one minute, starting with F, then A, then S. Proper nouns and previously used words with a different suffix are prohibited (Benton, 1968).

Other categorical fluency tests include naming animals, fruits and vegetables (Monsch et al, 1992).

For a formal result, it is necessary to test under strict conditions, using norms. However, valuable information may be obtained without formal testing. Generally, a normal individual will be able to provide more than ten items for each of these categories, while a patient with significant deficits will usually score less than eight. The performance of the task will also provide valuable information. Common errors include perseveration (repeating words which have already been given either during the task at hand or an earlier task). There may also be inappropriate or profane utterances. (These also suggest disinhibition which is discussed under orbitofrontal cortex, below.)

5. Alternating hand sequences. These can be devised by the examiner. One example is that one hand is placed palm upwards and the other is place palm downwards, and the patient is then asked to reverse these positions as rapidly as possible.

Another example is that the backs of the hands are both placed downwards, but one hand is clenched and the other is open, then the patients is asked to close the open hand and open the closed hand, and keep reversing the posture of the hands as rapidly as possible.

A final example is that the patient taps twice with one fist and once with the other, then after the rhythm is established, the patient is asked to change over the number of beats (the fist which first tapped twice now taps only once).

Patients with frontal lobe deficits usually perform poorly on these tests, often being unable to follow the relatively simple instructions.

6. Formal neuropsychological may be necessary where uncertainty remains. Commonly employed tests include Controlled Oral Word Association Test (Benton, 1968) and the Wisconsin Card Sorting Tests (Heaton, 1985).

Head injury and dementing illnesses may result in severe impairment of the executive functions. Schizophrenia often has thought disorder as a major feature and the executive functions tests are usually also at least mildly affected. Depressive disorder may be associated with poor performance on verbal fluency tests during the acute phase, which normalizes with remission (Trichard, *et al.*, 1995).

Orbital and basal area (Orbitofrontal cortex)

The orbitofrontal cortex is Brodmann areas 10 and 11. (Part of area 10 is mentioned above as contributing to the DLPC.) It mediates empathic, civil and socially appropriate behavior (Mega and Cummings, 1994). Much of the personality change described in cases of frontal lobe injury (Phineas Gage being the most famous) is due to lesions in this area. Patients may become irritable, labile, disinhibited and fail to respond to the conventions of acceptable social behavior. Similar changes may occur with lesions of subcortical element of the frontal-subcortical circuit, as with caudate damage in Huntington's disease.

Increased concern about social behavior and contamination has been associated with increased orbitofrontal and caudate metabolism. This has been reported with lesions of the globus pallidus and in obsessive compulsive disorder.

Bedside tests:

1. Does the patient dress or behave in a way which suggests lack of concern with the feelings of others or without concern to accepted social customs.
2. Test sense of smell - coffee, cloves etc.
3. **Go/no-go Test.** The patient is asked to make a response to one signal (the Go signal) and not to respond to another signal (the no-go signal). The most basic is to ask the patient to tap their knee when the examiner says, "Go" and to make no response when the examiner says, "Stop".

The task may be made more demanding by reversing the customary meaning of signals. An example is to ask the patient to tap the knee when the examiner says "Stop" and not to tap when the examiner says "Go" (Malloy and Richardson, 1994).

4. The **Stroop Test** (Stroop, 1935). This is a neuropsychological test which examines the ability of the patient to inhibit responses. Patients are asked to state the color in which words are printed rather than the words themselves, e.g., truck may be printed in blue, house may be printed in red.

This task is made difficult by presenting the name of colors printed in different colored ink. The task is to state the color of the ink, not to read the word. This is not as easy as it sounds. Try it now. Do it quickly, to increase the pressure.

Green	White	Purple
Blue	Red	Green
Pink	Orange	Blue
Purple	Yellow	Grey
Red	Green	Orange
Black	Blue	Red
White	Yellow	Pink

Cultural factors are important in making an observation of lack of civility, empathy and social concern. Eructation following a meal is considered good manners in some parts of the world, and people of the same race and city will have different sets of social values depending on socio-economic status.

Failure of inhibition may complicate head injury, other destructive lesions (including dementing processes) and schizophrenia. Failure of inhibition is found in impulse control and personality disorder (particularly of the antisocial type). Depressive disorder may manifest irritability, and has been associated with poor performance on the Stroop Test (Trichard et al, 1995).

Obsessive compulsive disorder in which there is excessive concern and caution is associated with increased metabolism in the orbitofrontal cortex (which may result from subcortical pathology; Hampson et al, 2012).

Supplementary motor area and anterior cingulate cortex

The supplementary motor area is the medial aspect of Brodmann area 6 (Barker & Barasi, 1999) and the anterior cingulate gyrus is Brodmann area 24. These areas are involved in motivated behavior (Mega and Cummings, 1994), initiation and goal-directed behavior (Devinsky et al, 1995).

At present there are no office or neuropsychological tests to measure the functional status of these areas.

Akinetic mutism occurs with gross lesions (e.g., meningioma) of the anterior cingulate. Such patients are profoundly apathetic, generally mute and eat and drink only when assisted. They do not respond to pain and are indifferent to their circumstances. Lesions of the supplementary motor area are associated with the alien hand syndrome (Goldberg & Bloom, 1990).

The apathy of schizophrenia and the immobility of depressive disorder may be associated with defects in associated circuits.

Frontal Release Reflexes

The primitive reflexes are present in normal babies. As the CNS matures, frontal lobe cells develop and begin to inhibit These may reappear with brain damage or disease - they may also reappear with normal aging. Their significance is greater when they appear unilaterally and in young individuals (Ross, 1985).

Grasp

The hand is stroked across the palm toward the thumb by the examiners fingers or the handle of the patella hammer. When the reflex is present the fingers grasp or the thumb strongly adducts. The patient may be unable to release the grip. Presence suggests contralateral frontal lobe disease.

Sucking (pout, snout, rooting)

The sucking reflex is elicited by stroking the lips of the patient with a finger or a spatula from side to middle and back again. The pouting reflex is elicited by the examiner placing the index finger of the patient's closed lips and tapping the finger with a patella hammer. Sucking or pouting movements of the lips suggest frontal lobe damage or bilateral lesions above the mid-pons.

Palmar-mental

The palm is scratched firmly with a key or the handle of the patella hammer, from the fingers, toward the wrist. The positive response is a flicker in the skin on the

ipsilateral side of the point of the chin. Presence suggests contralateral frontal lobe damage, however, the true value of the reflex is yet to be clearly determined.

Glabella Tap

The patient is asked to close the eyes and the examiner repeatedly taps (finger tip or patella hammer) the supraorbital ridge. In the normal individual the orbicularis oris contracts in response to the first two or three taps and then ceases. In pathological conditions the orbicularis oris continues to contract with every tap. This reflex is used in the diagnosis of Parkinson's disease, but it may also occur with frontal damage of other etiologies.

References

- Alexander G, DeLong M, Strick P. Parallel organization of functionally segregated circuits linking basal ganglia and cortex. *Annual Reviews of Neuroscience* 1986; 9:357-381.
- Alvarez J, Emory E. Executive function and the frontal lobes: a meta-analysis. *Neuropsychology Review* 2006; 16:17-42.
- Barker R, Barasi S. *Neuroscience at a glance*. Blackwell Science Ltd: Oxford. 1999.
- Benton A. Differential behavioral effects in frontal lobe disease. *Neuropsychologia* 1968; 6:53-60.
- Devinsky O, Morrell M, Vogt B. Contributions of anterior cingulate cortex to behavior. *Brain* 1995; 118:279-306.
- Goldberg G, Bloom K. The alien hand sign: localization, lateralization and recovery. *American Journal of Physical Medicine and rehabilitation* 1990; 69:228-238.
- Goldman-Rakic P. Circuitry of the primate prefrontal cortex and regulation of behavior by representational memory. In F Plum, V Mountcastle Eds. *Handbook of physiology, the nervous system, and higher functions of the brain* (Sec 1, Vol 5, pp 373-417. Bethesda, MD, American Psychological Society, 1987.
- Hampson M, Stoica T, Scheinost D, et al. Real-time fMRI biofeedback targeting the orbitofrontal cortex for contamination anxiety. *J Vis Exp* 2012; in press.
- Heaton R. *Wisconsin card sorting test*. Odessa, TX: Psychological Assessment Resources. 1985.
- Horn H, Federspiel A, Wirth M. et al. Gray matter volume differences specific to formal thought disorder in schizophrenia. *Psychiatry Research: Neuroimaging* 2010; 182:183-186.
- McGrath J. Ordering thoughts on thought disorder. *British Journal of Psychiatry* 1991; 158:683-688.
- Malloy P, Richardson E. Assessment of frontal lobe functions. *Journal of Neuropsychiatry and Clinical Neurosciences* 1994; 6:399-410.
- Mega M, Cummings J. Frontal-subcortical circuits and neuropsychiatric disorders. *Journal of Neuropsychiatry and Clinical Neurosciences* 1994; 6:358-370.
- Monsch A, Bondi M, Butters N. Comparisons of verbal fluency tasks in detection of dementia of the Alzheimer type. *Archives of Neurology* 1992; 49:1253-1258.
- Trichard C, Martinot J, Alagille M, Masure M, Hardy P, Ginstet D, Feline A. Time course of prefrontal dysfunction in severely depressed in-patients: a longitudinal neuropsychological study. *Psychological Medicine* 1995; 25:79-85.